

## CLINICAL PRACTICE

## Genital Herpes

David W. Kimberlin, M.D., and Dwight J. Rouse, M.D., M.S.P.H.

*This Journal feature begins with a case vignette highlighting a common clinical problem. Evidence supporting various strategies is then presented, followed by a review of formal guidelines, when they exist. The article ends with the authors' clinical recommendations.*

**A 22-year-old woman presents to her gynecologist with genital lesions. Examination reveals bilateral labial ulcerations (Fig. 1), cervical ulcerations, and mildly tender inguinal lymphadenopathy. To her knowledge, neither she nor any of the four sexual partners she has had, including her husband of two years, has ever had herpes. How should this patient's case be managed?**

## THE CLINICAL PROBLEM

## EPIDEMIOLOGY

Genital herpes is caused by herpes simplex virus type 1 (HSV-1) or herpes simplex virus type 2 (HSV-2). The primary route of acquisition of HSV-2 infections is through genital-genital sexual contact with an infected partner who is shedding virus symptomatically or asymptotically, and the risk of infection correlates with the number of lifetime sexual partners.<sup>1</sup> Since the late 1970s, the seroprevalence rates for HSV-2 in the United States have increased by 30 percent.<sup>1</sup> One in four persons 30 years of age or older in the United States has HSV-2,<sup>1</sup> although most do not realize that they have been infected. The prevalence of genital HSV-1 infection, which is usually acquired through oral-genital contact, has also increased dramatically and accounts for approximately 20 percent of current cases of genital herpes in the United States.<sup>2</sup>

## NATURAL HISTORY OF INFECTION

After the initial acquisition of HSV (primary infection), the viral genome resides in a latent state in the neuronal bodies indefinitely. Periodic reactivation (recurrent infection) results in either symptomatic infection (clinically apparent lesions) or asymptomatic infection.

*Initial Infection*

The average incubation period after the genital acquisition of HSV-1 or HSV-2 is approximately 4 days (range, 2 to 12). Local and systemic symptoms associated with primary HSV-1 infection are generally of the same intensity as those associated with primary HSV-2 infection.<sup>3</sup> In its "classic" clinical presentation, primary infection begins with macules and papules and progresses to vesicles, pustules, and ulcers.<sup>3</sup> Skin ulcers crust (Fig. 2), whereas lesions in the mucous membrane heal without crusting. Most patients with primary genital herpes, however, do not have these "classic" symptoms.<sup>5</sup>

The overwhelming majority of both men and women with a first episode of clinically apparent genital HSV-2 disease have localized symptoms, such as pain at the site of the lesions and tender regional adenopathy (Fig. 2). Urethritis and cervicitis may occur with genital acquisition, and pharyngitis may occur with oral acquisition. Constitutional symptoms such as fever, headache, malaise, and myalgias are present in two thirds of women and approximately 40 percent of men with such a clinically apparent first episode.

From the Departments of Pediatrics (D.W.K.) and Obstetrics and Gynecology (D.J.R.), University of Alabama at Birmingham, Birmingham. Address reprint requests to Dr. Kimberlin at the Division of Pediatric Infectious Diseases, University of Alabama at Birmingham, 1600 Seventh Ave. S., CHB 303, Birmingham, AL 35233, or at dkimberlin@peds.uab.edu.

N Engl J Med 2004;350:1970-7.  
Copyright © 2004 Massachusetts Medical Society.

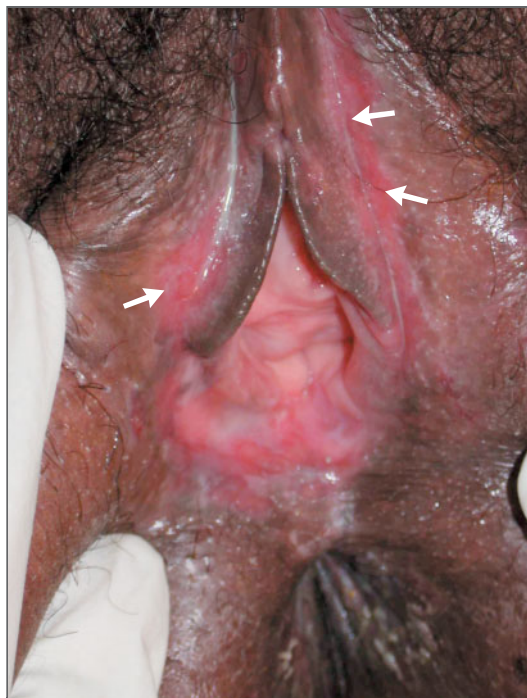
First episodes of nonprimary infections (acquisition of HSV-2 in persons with preexisting antibodies against HSV-1 or, more rarely, acquisition of HSV-1 in persons with preexisting antibodies against HSV-2) are less commonly associated with systemic symptoms than are first episodes of primary infections (acquisition of HSV-1 or HSV-2 in persons with no preexisting anti-HSV antibody); such symptoms occur in 16 percent of recognized cases of nonprimary infections and 62 percent of recognized cases of primary infections. Nonprimary infections are also associated with lower rates of complications than primary infections, a shorter duration of disease (mean, 9 days vs. 12 days), a shorter duration of viral shedding (mean, 7 days vs. 11 days), and fewer lesions (mean, 10 vs. 16).<sup>6</sup> In at least 10 percent of first clinical episodes of symptomatic genital herpes (and probably a much higher proportion), serologic evidence of HSV-2 infection indicates that there has been previous asymptomatic acquisition of the virus.<sup>7</sup>

#### Recurrent Infection

Recurrences of genital HSV-2 infection may be symptomatic<sup>3</sup> or, more commonly, asymptomatic.<sup>8</sup> Approximately half of patients who recognize recurrences have prodromal symptoms, ranging from mild tingling sensations occurring 30 minutes to 48 hours before the eruption to shooting pains in the buttocks, legs, or hips occurring as long as five days before the eruption.<sup>4</sup> The duration of viral shedding is shorter in recurrences than in primary infection (mean, 4 days vs. 11 days), and there are fewer lesions present (mean, 6 lesions vs. 16 lesions).

Within 12 months after diagnosis, 90 percent of patients with a documented first episode of genital HSV-2 infection have at least 1 recurrence, 38 percent have 6 or more recurrences, and 20 percent have 10 or more recurrences.<sup>9</sup> Genital HSV-1 infections recur less frequently than do genital HSV-2 infections, explaining why most cases of symptomatic HSV-1 genital disease are primary cases.<sup>3</sup> Irrespective of viral type and whether or not suppressive therapy is used, recurrence rates decrease over time.<sup>10</sup>

Asymptomatic viral shedding accounts for much of the transmission of HSV.<sup>11</sup> HSV DNA can be detected by means of polymerase chain reaction (PCR) in genital specimens from HSV-2-seropositive women on 28 percent of days,<sup>12</sup> and the virus may be transmitted to a sexual partner during such periods of subclinical shedding.<sup>13</sup> Although the risk of



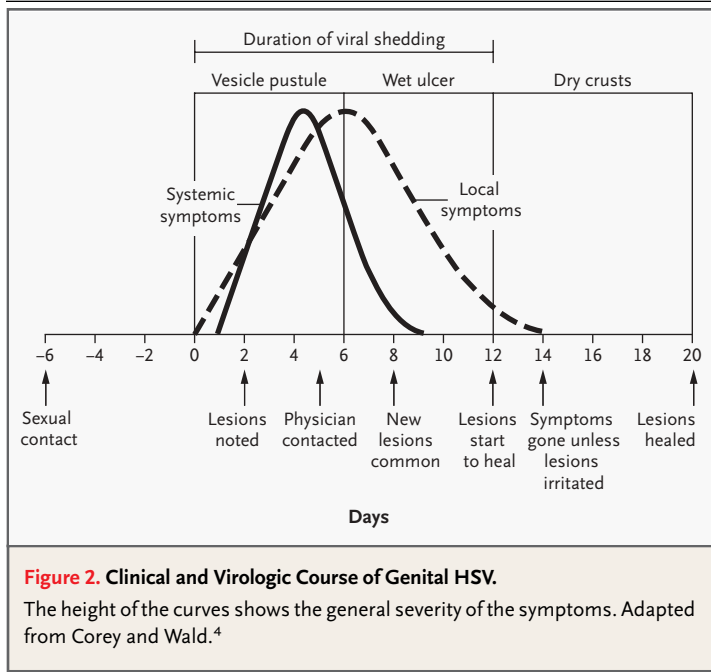
**Figure 1. Genital Herpes Simplex Virus Ulcerations (Arrows).**

Courtesy of Jay Sizemore, M.D., University of Alabama at Birmingham.

transmission of HSV-2 from an infected person to a susceptible sexual partner is higher when genital lesions are present<sup>14</sup> (because asymptomatic shedding occurs much more frequently than symptomatic disease), most experts believe that transmission results from asymptomatic shedding in most cases.<sup>14</sup> In one study involving 13 couples who were discordant for HSV seropositivity, transmission occurred in 9 couples (69 percent) when the source partner was reported to be asymptomatic, whereas in the other 4 couples (31 percent) it resulted from sexual contact during the prodrome (in 1 case) or within hours before lesions were first noticed by the source partner (in 3 cases).<sup>14</sup> Direct contact other than sexual intercourse can result in viral spread if an area of viral shedding comes into contact with the skin or mucous membranes of a susceptible person.

#### Neurologic Complications

Central nervous system complications of genital herpes include aseptic meningitis, sacral radiculopathy, transverse myelitis, and benign recurrent lymphocytic meningitis (Mollaret's meningitis).<sup>3,15</sup> Of



these complications, aseptic meningitis is the most frequent, and in the majority of cases, it occurs in association with primary infection. Approximately one third of women and 1 in 10 men with primary infection have meningeal signs, whereas such signs are rare among patients with nonprimary infection.

#### Neonatal HSV

Perhaps the most serious manifestation of HSV is neonatal disease, which is usually vertically acquired. Signs of infection in infants, which generally appear at two to three weeks of age, include skin vesicles, fever, irritability, seizures, hepatitis, pneumonitis, and disseminated intravascular coagulopathy. Infants born to mothers who have a first episode of genital HSV infection near the time of delivery are at much greater risk than offspring of mothers with recurrent genital herpes.<sup>4,16</sup> Despite advances in the diagnosis and management of neonatal herpes, morbidity and mortality remain high.<sup>17,18</sup>

#### Human Immunodeficiency Virus Infection

Genital ulcer disease, including that caused by HSV-2, is a well-recognized risk factor for the transmission of human immunodeficiency virus (HIV).<sup>19</sup> High titers of HIV are found in genital herpes ulcerations,<sup>20</sup> and the plasma HIV viral load increases when HSV-2 infection is reactivated in HIV-infected

persons.<sup>21</sup> It is likely that many new HIV infections are attributable to underlying genital HSV infection.<sup>19</sup>

#### STRATEGIES AND EVIDENCE

Viral culture is widely available and results in the isolation of the virus within approximately five days. The sensitivity of the culture, however, depends on the stage of the episode (Fig. 2). About 95 percent of vesicular lesions will grow HSV, as compared with 70 percent of ulcerative lesions and 30 percent of crusted lesions. Because primary infection is associated with a greater viral load than recurrent disease (greater than  $10^6$  virions vs.  $10^2$  to  $10^3$  virions per 0.2 ml of inoculum), the yield from viral culture is also higher with primary infection than with recurrent infection. Antigen-detection methods are commercially available but may not be useful in distinguishing HSV-1 from HSV-2. PCR may be used to confirm the diagnosis of genital HSV infection and may be useful in diagnosis when lesions have already crusted; however, it is more expensive than viral culture and is not routinely used.

In the past few years, two type-specific antibody assays<sup>22</sup> have received approval from the Food and Drug Administration: the HerpeSelect HSV-1 and HSV-2 enzyme-linked immunosorbent assays and HSV-1 and HSV-2 immunoblot tests (Focus Technologies). Several additional tests that are purported to be capable of distinguishing between anti-HSV-1 and anti-HSV-2 antibodies are commercially available, but they have high rates of cross-reactivity that limit their usefulness in distinguishing between the two types of virus.<sup>23</sup> Type-specific serologic testing for HSV may be useful for diagnosis in patients with symptomatic genital disease who have healing lesions (in whom culture is likely to be negative) and may also be used in screening (as described below).

#### DIFFERENTIAL DIAGNOSIS

The differential diagnosis of labial ulcerations consists primarily of genital herpes, primary syphilis, and chancroid. Primary syphilis, caused by *Treponema pallidum*, is characterized by one or more painless, indurated ulcers occurring at the site of inoculation. Chancroid ulcerations, caused by *Haemophilus ducreyi*, are typically painful, tender, nonindurated lesions characterized by a serpiginous border surrounding a friable base covered with gray or yellow, necrotic, purulent exudate. A painful, unilateral in-

ginal adenitis is present in half of cases. Noninfectious conditions that can mimic genital herpes include Crohn's disease, Behçet's syndrome, trauma, contact dermatitis, erythema multiforme, Reiter's syndrome, psoriasis, and lichen planus.

#### TREATMENT

The acyclic nucleoside analogues acyclovir, valacyclovir, and famciclovir are available for the management of genital herpes.<sup>24</sup> All are effective for the treatment of a first episode of genital herpes,<sup>25-27</sup> for episodic treatment of recurrent genital herpes,<sup>28-32</sup> and when taken daily for the prevention of a clinical recurrence (suppressive therapy).<sup>33-36</sup> Information on doses, anticipated efficacy, and advantages and disadvantages of each antiviral agent are presented in Table 1.

If episodic therapy is used, it should be started at the first sign of a recurrence, including during the prodromal period if one is recognized. Patients should be educated regarding the manifestations of genital herpes and should have a supply of antiviral medication to use as needed. Topical acyclovir provides no benefit in the episodic treatment of genital herpes and is not recommended.

Several observations support the use of suppressive therapy, rather than episodic treatment of recurrences. Most persons with a first episode of genital herpes are at risk for frequent recurrences over the next few years.<sup>9</sup> Suppressive therapy substantially reduces the likelihood of symptomatic recurrence,<sup>33-37</sup> as well as the frequency of subclinical (asymptomatic) viral shedding<sup>12,38-40</sup> (Table 1), and results in better quality of life for patients with frequent recurrences than does episodic treatment.<sup>41</sup> Suppressive therapy is also safe<sup>33-36</sup> and reduces the risk of transmission of HSV to uninfected partners.<sup>42</sup> In a recent study, suppressive therapy with 500 mg of valacyclovir once daily for eight months decreased the rate of symptomatic HSV infection in the seronegative partner by 75 percent and reduced the likelihood of acquisition of genital HSV-2 infection (symptomatic or asymptomatic) by 48 percent.<sup>42</sup>

#### PSYCHOLOGICAL EFFECTS OF GENITAL HERPES

Despite the advances in our understanding of genital herpes, many infected persons continue to feel considerable embarrassment and a sense of stigma.<sup>41</sup> For many patients, the psychological effects are far more severe than the physical consequences of the disease.<sup>43</sup> Shock, anger, guilt, low self-

esteem, fear of transmitting the infection to others, and impaired sexual function are common and can interfere substantially with relationships.<sup>41</sup> In one study, more than 80 percent of persons with genital herpes strongly agreed that it would be "an enormous weight" off their minds if they knew they were unlikely to have another attack, and more than 70 percent strongly agreed that their biggest fear is of transmitting herpes to someone else; approximately 60 percent strongly agreed that they were "devastated" when first told of their diagnosis.<sup>41,44</sup> In another study, one third of patients with genital herpes reported having felt depressed or sad for much of the previous year or on most days for two or more years. Furthermore, scores for mental and physical health were significantly lower among patients with genital herpes than in the population at large.<sup>44</sup> Unfortunately, many physicians do not appreciate the psychological import of the diagnosis and may focus exclusively on the treatment of the physical symptoms.<sup>41,44</sup>

#### SCREENING

Type-specific serologic testing for HSV has been advocated for the screening of patients who have risk factors for HSV (such as HIV infection, other sexually transmitted diseases, multiple partners, or a partner with a history of HSV infection) but no history of genital herpetic lesions.<sup>23</sup> Routine screening of patients who are at low risk for disease is not recommended because of the potential for false positive results.

---

### AREAS OF UNCERTAINTY

---

#### REDUCING THE RISK OF TRANSMISSION TO A SERONEGATIVE PARTNER

The optimal approach to preventing the transmission of HSV to uninfected persons in practice remains uncertain. Condom use is one effective strategy. A recent study of 528 monogamous couples who were discordant for HSV-2 infection found that when condoms were used during more than 70 percent of sexual encounters between an HSV-2-positive man and an HSV-2-negative woman, the risk of transmission was reduced by more than 60 percent.<sup>45</sup> The best way of achieving more consistent condom use by such couples, however, remains to be determined. As discussed above, another approach is the use of antiviral suppressive therapy in the seropositive partner.<sup>42</sup> Neither approach, however, completely eliminates the risk of transmission.

**Table 1. Therapeutic Management of Genital Herpes.\***

Agent	Dose and Schedule†	Efficacy	Advantages and Disadvantages Relative to Other Agents
<b>First episode of genital herpes</b>			
Acyclovir	200 mg orally 5 times/day for 7–10 days or 400 mg orally 3 times/day for 7–10 days	2-Day decrease in time to resolution of signs and symptoms; 4-day decrease in time to healing of lesions; 7-day decrease in duration of viral shedding	Less expensive, smaller tablets; liquid formulation available; less convenient treatment schedule
Valacyclovir	1000 mg orally twice daily for 7–10 days	No difference in efficacy as compared with acyclovir for first episode	More convenient treatment schedule; more expensive, larger caplets; no liquid formulation
Famciclovir	250 mg orally three times/day for 7–10 days	No difference in efficacy as compared with acyclovir for first episode	More convenient treatment schedule; smaller tablets; more expensive; no liquid formulation
<b>Recurrent genital herpes, episodic treatment‡</b>			
Acyclovir	200 mg orally 5 times/day for 5 days or 800 mg orally twice daily for 5 days	1.1-Day decrease in time to resolution of signs and symptoms; 1.2-day decrease in time to healing of lesions; 2.0-day decrease in duration of viral shedding	Same as for first episode
Valacyclovir	500 mg orally twice daily for 3 or 5 days or 1000 mg orally once daily for 5 days	No difference in efficacy as compared with acyclovir for episodic treatment	Same as for first episode
Famciclovir	125 mg orally twice daily for 5 days	No difference in efficacy as compared with acyclovir for episodic treatment	Same as for first episode
<b>Suppressive therapy¶</b>			
Acyclovir	400 mg twice daily	71% of recipients recurrence-free after 4 mo; 80–94% reduction in no. of days with subclinical shedding	Same as for first episode
Valacyclovir	500 mg once daily (for patients with 9 or fewer recurrences/yr) or 1000 mg once daily	69% of recipients recurrence-free after 4 mo; 81% reduction in no. of days with subclinical shedding	Same as for first episode
Famciclovir	250 mg twice daily	78% of recipients recurrence-free after 4 mo; 87% reduction in no. of days with subclinical shedding	Same as for first episode

\* Data were modified from Sexually Transmitted Diseases Treatment Guidelines 2002.<sup>24</sup> Allergic and other adverse reactions to acyclovir, valacyclovir, and famciclovir are rare.

† For the first episode of genital herpes, the range of duration of therapy reflects differences in the durations of treatment in the original clinical studies. If the shorter course of therapy is prescribed initially, the patient should be reevaluated toward the end of treatment, and therapy should be continued if new lesions continue to form, if complications develop, or if systemic signs and symptoms have not abated. Episodic therapy should be started within 24 hours after the onset of a recurrence, or as soon as possible thereafter.

‡ The recommendations for episodic treatment in HIV-infected persons are as follows: acyclovir, 200 mg five times per day for 5 to 10 days or 400 mg three times per day for 5 to 10 days; valacyclovir, 1000 mg twice daily for 5 to 10 days; or famciclovir, 500 mg twice daily for 5 to 10 days.

¶ The recommendations for suppressive therapy in HIV-infected persons are as follows: acyclovir, 400 to 800 mg two or three times per day; valacyclovir, 500 mg twice daily; or famciclovir, 500 mg twice daily.

### REDUCING VERTICAL TRANSMISSION OF HSV INFECTION

Several small randomized studies have suggested that suppressive acyclovir therapy during the last four weeks or so of pregnancy in women with a history of genital herpes decreases the occurrence of clinically apparent genital HSV disease at the time of delivery,<sup>46-48</sup> with an associated decrease in the rate of cesarean sections performed because of genital HSV.<sup>46,47</sup> However, because viral shedding still occurs (albeit with reduced frequency),<sup>48,49</sup> neonatal infection is still possible. Additional studies are needed of the effectiveness of suppressive therapy in late pregnancy and the risks associated with it, including the risk of neonatal neutropenia.<sup>18,50,51</sup> There are currently insufficient data to justify the routine use of suppressive therapy in pregnant women who have had genital herpes. In addition, the role of type-specific serologic testing in pregnant women requires further study.<sup>52</sup>

### HSV VACCINATION

An HSV-2 glycoprotein-D–subunit vaccine was recently demonstrated to be safe and, in women who were seronegative for HSV-1 and HSV-2 before vaccination, reasonably effective in preventing clinically apparent HSV-1 or HSV-2 genital herpes disease (efficacy, 75 percent).<sup>53</sup> The vaccine was not effective in men, nor was it effective in women with pre-existing anti-HSV-1 antibodies. Further study of this vaccine in women who are seronegative for HSV-1 and HSV-2 is under way.

### RESISTANT HSV INFECTIONS

HSV infections that are resistant to acyclovir, valacyclovir, or famciclovir are rare, and when they occur, they are usually in immunocompromised persons. Acyclovir-resistant isolates are usually resistant to famciclovir also but are typically susceptible to foscarnet and cidofovir.<sup>54</sup> As antiviral agents against HSV are used with increasing frequency, monitoring is warranted for the possible emergence of resistant isolates from immunocompetent persons.

---

## GUIDELINES

---

In 2002, the Centers for Disease Control and Prevention (CDC) released updated treatment guidelines for the management of genital herpes (Table 1).<sup>24</sup> These guidelines also address serologic screening in patients who are at high risk for HSV infec-

tion, including those with HIV infection, and consideration of suppressive therapy in HIV-infected patients who are seropositive for HSV. In 1999, the American College of Obstetricians and Gynecologists updated its management guidelines for genital herpes in pregnancy.<sup>55</sup> The International Herpes Management Forum ([www.ihmf.org](http://www.ihmf.org)) also provides management guidelines, which generally agree with the recommendations of the CDC.

---

## SUMMARY AND RECOMMENDATIONS

---

All patients with a first clinical episode of genital herpes, such as the patient in the vignette, should be treated for 7 to 10 days with systemic antiviral therapy (acyclovir, valacyclovir, or famciclovir). Therapy should be extended if healing is incomplete after 10 days of therapy.<sup>24</sup> After this treatment, patients should be educated about the potential benefits of suppressive therapy and offered this treatment. Counseling should include discussion of the risk of frequent recurrences during the next few years if suppressive therapy is not used, as well as the benefits of suppressive therapy in preventing transmission to uninfected partners. The choice of drug will depend on cost, convenience, and formulation.

Lesions should be cultured for HSV. However, treatment for clinically suspected disease should not be delayed pending the culture result. Because false negative HSV cultures can occur in patients with recurrent infection or with healing lesions,<sup>4</sup> type-specific serologic testing should be performed at the time of an initial episode and, if negative, repeated three months later.<sup>23</sup> Type-specific serologic analysis can also aid in the classification of infection as primary, nonprimary, or recurrent, and thus may guide counseling.

Possible concerns regarding infidelity should be addressed directly. Patients should understand that many first clinical episodes of symptomatic genital herpes actually represent recurrent infection<sup>7</sup> and that a new diagnosis of genital herpes in a member of a monogamous couple does not necessarily imply recent acquisition of infection from another partner.

If suppressive therapy is begun, patients should be asked approximately yearly whether they wish to continue it. The frequency of genital recurrences decreases over time for both patients who receive suppressive therapy and those who do not,<sup>10</sup> and a drug holiday allows for reassessment of whether suppression is still needed.

All persons with genital herpes should be edu-

cated about the risk of transmission to partners, even when they are asymptomatic. Serologic testing and counseling of current partners should be offered, if appropriate.<sup>23</sup> HSV-infected patients with seronegative partners should be counseled to refrain from sexual intercourse during clinical recurrences,<sup>14</sup> encouraged to use condoms,<sup>45</sup> and offered antiviral suppression to decrease the risk of transmis-

sion.<sup>42</sup> However, they should also understand that the risk of transmission is not completely eliminated even with these approaches.<sup>11-14,42,45</sup>

Supported by contracts (NO1-AI-15113 and NO1-AI-62554, to Dr. Kimberlin) with the Virology Branch, Division of Microbiology and Infectious Diseases of the National Institute of Allergy and Infectious Diseases; a grant (RR-032) from the General Clinical Research Center Program and the State of Alabama; and a grant (NICHD 1 K24HD01375-01, to Dr. Rouse) from the National Institute of Child Health and Human Development.

## REFERENCES

- Fleming DT, McQuillan GM, Johnson RE, et al. Herpes simplex virus type 2 in the United States, 1976 to 1994. *N Engl J Med* 1997;337:1105-11.
- Lafferty WE, Downey L, Celum C, Wald A. Herpes simplex virus type 1 as a cause of genital herpes: impact on surveillance and prevention. *J Infect Dis* 2000;181:1454-7.
- Corey L, Adams HG, Brown ZA, Holmes KK. Genital herpes simplex virus infections: clinical manifestations, course, and complications. *Ann Intern Med* 1983;98:958-72.
- Corey L, Wald A. Genital herpes. In: Holmes KK, Mardh P-A, Sparling PF, et al., eds. *Sexually transmitted diseases*. 3rd ed. New York: McGraw-Hill, 1999:285-312.
- Koutsky LA, Stevens CE, Holmes KK, et al. Underdiagnosis of genital herpes by current clinical and viral-isolation procedures. *N Engl J Med* 1992;326:1533-9.
- Kaufman RH, Gardner HL, Rawls WE, Dixon RE, Young RL. Clinical features of herpes genitalis. *Cancer Res* 1973;33:1446-51.
- Diamond C, Selke S, Ashley R, Benedetti J, Corey L. Clinical course of patients with serologic evidence of recurrent genital herpes presenting with signs and symptoms of first episode disease. *Sex Transm Dis* 1999;26:221-5.
- Ratray MC, Corey L, Reeves WC, Vontver LA, Holmes KK. Recurrent genital herpes among women: symptomatic v. asymptomatic viral shedding. *Br J Vener Dis* 1978;54:262-5.
- Benedetti J, Corey L, Ashley R. Recurrence rates in genital herpes after symptomatic first-episode infection. *Ann Intern Med* 1994;121:847-54.
- Benedetti JK, Zeh J, Corey L. Clinical reactivation of genital herpes simplex virus infection decreases in frequency over time. *Ann Intern Med* 1999;131:14-20.
- Wald A, Zeh J, Selke S, et al. Reactivation of genital herpes simplex virus type 2 infection in asymptomatic seropositive persons. *N Engl J Med* 2000;342:844-50.
- Wald A, Corey L, Cone R, Hobson A, Davis G, Zeh J. Frequent genital herpes simplex virus 2 shedding in immunocompetent women: effect of acyclovir treatment. *J Clin Invest* 1997;99:1092-7.
- Rooney JF, Felsler JM, Ostrove JM, Straus SE. Acquisition of genital herpes from an asymptomatic sexual partner. *N Engl J Med* 1986;314:1561-4.
- Mertz GJ, Benedetti J, Ashley R, Selke SA, Corey L. Risk factors for the sexual transmission of genital herpes. *Ann Intern Med* 1992;116:197-202.
- Berger JR. Benign aseptic (Mollaret's) meningitis after genital herpes. *Lancet* 1991;337:1360-1.
- Brown ZA, Wald A, Morrow RA, Selke S, Zeh J, Corey L. Effect of serologic status and cesarean delivery on transmission rates of herpes simplex virus from mother to infant. *JAMA* 2003;289:203-9.
- Kimberlin DW, Lin CY, Jacobs RF, et al. Safety and efficacy of high-dose intravenous acyclovir in the management of neonatal herpes simplex virus infections. *Pediatrics* 2001;108:230-8.
- Kimberlin D, Powell D, Gruber W, et al. Administration of oral acyclovir suppressive therapy after neonatal herpes simplex virus disease limited to the skin, eyes and mouth: results of a phase I/II trial. *Pediatr Infect Dis J* 1996;15:247-54.
- Corey L, Handsfield HH. Genital herpes and public health: addressing a global problem. *JAMA* 2000;283:791-4.
- Schacker T, Ryncarz AJ, Goddard J, Diem K, Shaughnessy M, Corey L. Frequent recovery of HIV-1 from genital herpes simplex virus lesions in HIV-1-infected men. *JAMA* 1998;280:61-6.
- Mole L, Ripich S, Margolis D, Holodniy M. The impact of active herpes simplex virus infection on human immunodeficiency virus load. *J Infect Dis* 1997;176:766-70.
- Prince HE, Ernst CE, Hogrefe WR. Evaluation of an enzyme immunoassay system for measuring herpes simplex virus (HSV) type 1-specific and HSV type 2-specific IgG antibodies. *J Clin Lab Anal* 2000;14:13-6.
- Ashley RL. Sorting out the new HSV type specific antibody tests. *Sex Transm Infect* 2001;77:232-7.
- Sexually transmitted diseases treatment guidelines 2002. *MMWR Recomm Rep* 2002;51(RR-6):1-78.
- Mertz GJ, Critchlow CW, Benedetti J, et al. Double-blind placebo-controlled trial of oral acyclovir in first-episode genital herpes simplex virus infection. *JAMA* 1984;252:1147-51.
- Fife KH, Barbarash RA, Rudolph T, DeGregorio B, Roth R. Valaciclovir versus acyclovir in the treatment of first-episode genital herpes infection: results of an international, multicenter, double-blind, randomized clinical trial. *Sex Transm Dis* 1997;24:481-6.
- Loveless M, Harris W, Sacks S. Treatment of first episode genital herpes with famciclovir. In: Program and abstracts of the 35th Interscience Conference on Antimicrobial Agents and Chemotherapy, San Francisco, September 17-20, 1995. Washington, D.C.: American Society for Microbiology, 1995:181. abstract.
- Tyring SK, Douglas JM Jr, Corey L, Spruance SL, Esmann J. A randomized, placebo-controlled comparison of oral valacyclovir and acyclovir in immunocompetent patients with recurrent genital herpes infections. *Arch Dermatol* 1998;134:185-91.
- Bodsworth NJ, Crooks RJ, Borelli S, et al. Valaciclovir versus aciclovir in patient initiated treatment of recurrent genital herpes: a randomised, double blind clinical trial. *Genitourin Med* 1997;73:110-6.
- Sacks SL, Aoki FY, Diaz-Mitoma F, Sellers J, Shafran SD. Patient-initiated, twice-daily oral famciclovir for early recurrent genital herpes: a randomized, double-blind multicenter trial. *JAMA* 1996;276:44-9.
- Chosidow O, Drouault Y, Leconte-Veyriac F, et al. Famciclovir vs. aciclovir in immunocompetent patients with recurrent genital herpes infections: a parallel-groups, randomized, double-blind clinical trial. *Br J Dermatol* 2001;144:818-24.
- Spruance SL, Tyring SK, DeGregorio B, Miller C, Beutner K. A large-scale, placebo-controlled, dose-ranging trial of peroral valaciclovir for episodic treatment of recurrent herpes genitalis. *Arch Intern Med* 1996;156:1729-35.
- Douglas JM, Critchlow C, Benedetti J, et al. A double-blind study of oral acyclovir for suppression of recurrences of genital herpes simplex virus infection. *N Engl J Med* 1984;310:1551-6.
- Patel R, Bodsworth NJ, Woolley P, et al. Valaciclovir for the suppression of recurrent genital HSV infection: a placebo controlled study of once daily therapy. *Genitourin Med* 1997;73:105-9.
- Reitano M, Tyring S, Lang W, et al. Valaciclovir for the suppression of recurrent genital herpes simplex virus infection: a large-scale dose range-finding study. *J Infect Dis* 1998;178:603-10.
- Mertz GJ, Loveless MO, Levin MJ, et al. Oral famciclovir for suppression of recurrent genital herpes simplex virus infection

- in women: a multicenter, double-blind, placebo-controlled trial. *Arch Intern Med* 1997; 157:343-9.
37. Mertz GJ, Jones CC, Mills J, et al. Long-term acyclovir suppression of frequently recurring genital herpes simplex virus infection: a multicenter double-blind trial. *JAMA* 1988;260:201-6.
38. Wald A, Zeh J, Barnum G, Davis LG, Corey L. Suppression of subclinical shedding of herpes simplex virus type 2 with acyclovir. *Ann Intern Med* 1996;124:8-15.
39. Wald A, Warren T, Hu H, et al. Suppression of subclinical shedding of herpes simplex virus type 2 in the genital tract with valaciclovir. In: Program and abstracts of the 38th Interscience Conference on Antimicrobial Agents and Chemotherapy, San Diego, Calif., September 24-27, 1998. Washington, D.C.: American Society for Microbiology, 1998:338. abstract.
40. Sacks SL, Hughes A, Rennie B, Boon R. Famciclovir for suppression of asymptomatic and symptomatic recurrent genital herpes shedding: a randomized, double-blind, double-dummy, parallel-group, placebo-controlled trial. In: Program and abstracts of the 37th Interscience Conference on Antimicrobial Agents and Chemotherapy, Toronto, September 28-October 1, 1997. Washington, D.C.: American Society for Microbiology, 1997:227. abstract.
41. Alexander L, Naisbett B. Patient and physician partnerships in managing genital herpes. *J Infect Dis* 2002;186:Suppl 1:S57-S65.
42. Carney L, Wald A, Patel R, et al. Once-daily valacyclovir to reduce the risk of transmission of genital herpes. *N Engl J Med* 2004; 350:11-20.
43. Carney O, Ross E, Bunker C, Ikkos G, Mindel A. A prospective study of the psychological impact on patients with a first episode of genital herpes. *Genitourin Med* 1994;70:40-5.
44. Patel R, Boselli F, Cairo I, Barnett G, Price M, Wulf HC. Patients' perspectives on the burden of recurrent genital herpes. *Int J STD AIDS* 2001;12:640-5.
45. Wald A, Langenberg AG, Link K, et al. Effect of condoms on reducing the transmission of herpes simplex virus type 2 from men to women. *JAMA* 2001;285:3100-6.
46. Braig S, Luton D, Sibony O, et al. Acyclovir prophylaxis in late pregnancy prevents recurrent genital herpes and viral shedding. *Eur J Obstet Gynecol Reprod Biol* 2001;96: 55-8.
47. Scott LL, Sanchez PJ, Jackson GL, Zeray F, Wendel GD Jr. Acyclovir suppression to prevent cesarean delivery after first-episode genital herpes. *Obstet Gynecol* 1996;87:69-73.
48. Scott LL, Hollier LM, McIntire D, Sanchez PJ, Jackson GL, Wendel GD Jr. Acyclovir suppression to prevent recurrent genital herpes at delivery. *Infect Dis Obstet Gynecol* 2002;10:71-7.
49. Watts DH, Brown ZA, Money D, et al. A double-blind, randomized, placebo-controlled trial of acyclovir in late pregnancy for the reduction of herpes simplex virus shedding and cesarean delivery. *Am J Obstet Gynecol* 2003;188:836-43.
50. Kimberlin DW. Vertical transmission of HSV. *Int J STD AIDS* 2002;13:Suppl 1:60. abstract.
51. Sheffield JS, Hollier LM, Hill JB, Stuart GS, Wendel GD. Acyclovir prophylaxis to prevent herpes simplex virus recurrence at delivery: a systematic review. *Obstet Gynecol* 2003;102:1396-403.
52. Rouse DJ, Stringer JS. An appraisal of screening for maternal type-specific herpes simplex virus antibodies to prevent neonatal herpes. *Am J Obstet Gynecol* 2000;183:400-6.
53. Stanberry LR, Spruance SL, Cunningham AL, et al. Glycoprotein-D-adjuvant vaccine to prevent genital herpes. *N Engl J Med* 2002;347:1652-61.
54. Kimberlin DW, Crumacker CS, Straus SE, et al. Antiviral resistance in clinical practice. *Antiviral Res* 1995;26:423-38.
55. ACOG practice bulletin: management of herpes in pregnancy: number 8 October 1999: clinical management guidelines for obstetrician-gynecologists. *Int J Gynaecol Obstet* 2000;68:165-73.

Copyright © 2004 Massachusetts Medical Society.

#### IMAGES IN CLINICAL MEDICINE

The *Journal* welcomes consideration of new submissions for Images in Clinical Medicine. Instructions for authors and procedures for submissions can be found on the *Journal's* Web site at [www.nejm.org](http://www.nejm.org). At the discretion of the editor, images that are accepted for publication may appear in the print version of the *Journal*, the electronic version, or both.